

Unusual Severe Extra-Intestinal Manifestations of a Common Enteric Pathogen-*Aeromonas* Spp

BARNINI BANERJEE¹, MRIDULA MADIYAL², LINGADAKAI RAMCHANDRA³,
CHIRANJAY MUKHOPADHYAY⁴, RAHUL GARG⁵, KIRAN CHAWLA⁶

ABSTRACT

Introduction: *Aeromonas* spp. are halophilic, Gram-negative bacilli. They are widely distributed in the soil and aquatic environment and have been associated with various extra-intestinal infections, such as skin and soft-tissue infections, meningitis, bacteraemia etc. The most common species associated with extra-intestinal infection is *Aeromonas hydrophila*.

Aim: To get the overview of clinical presentations, underlying predisposing factors associated with the extra-intestinal infections caused by *Aeromonas* species and their antimicrobial susceptibility pattern.

Materials and Methods: Extra-intestinal cases of *Aeromonas* spp. admitted during December 2015 to October 2016 in the tertiary care hospital of South Karnataka coastal region were analysed retrospectively. The isolates were identified by Matrix Assisted Laser Desorption Ionization Time-of-Flight (MALDI-TOF) VITEK[®]MS and antimicrobial susceptibility testing was performed by VITEK[®]2 system (bioMérieux, Inc., Durham, NC) respectively. Clinical manifestations and management of the cases were noted from the clinical records. Clinical and microbiological findings presented as mean±standard deviation,

frequency and percentage.

Results: We included 26 cases in this study, from whom *Aeromonas* spp. were isolated alone or with another microorganism. Most widespread infection was Skin and Soft Tissue Infection (SSTI) (24, 92.3%). In 50% (12/24) cases, SSTI developed due to trauma. In 45.8% (11/24), underlying co-morbid conditions were present. The common site of infection was lower extremities (16/24, 66.7%) and 62.5% (15/24) of them presented with severe gangrene of the affected site. Other than SSTI, we encountered with two cases of keratitis and cholangitis respectively. *A. hydrophila* were frequently isolated species (23/26, 88.5%). The analysis of antimicrobial susceptibility showed, 13% isolates were Multidrug Resistant (MDR). Carbapenem resistance was also noted.

Conclusion: We had isolated *Aeromonas* spp. from different extra-intestinal sites. Most common extra-intestinal manifestation by this organism was post-traumatic wound infection. Clinical spectrum of this infection confused the clinician with other organisms like group B *Streptococcus*, *Clostridium* spp. etc., and mislead them in empirical management. Finally with the microbiological support all the cases were treated either conservatively or in combination with surgical debridement or amputation depending on the situation.

Keywords: Multidrug resistance, Trauma, Wound infection

INTRODUCTION

The *Aeromonas* are halophilic, Gram-negative, facultative anaerobic bacilli commonly found in the soil and aquatic environment [1]. They cause either gastrointestinal illness or a wide variety of extra-intestinal infections like SSTI, pneumonia, cholangitis, peritonitis, ophthalmic infection, septicaemia, etc., not only in immunocompetent but also in immunocompromised host [2]. Extra-intestinal infections occur due to direct contact with contaminated soil or water or indirectly by ingestion and bacteremic invasion from gastrointestinal tract [3]. Despite knowing that, *Aeromonas* is a significant human pathogen and shows resistant to commonly used drugs like penicillin, ampicillin and first generation cephalosporin [1]. Most of the time, it is overlooked or reported as a contaminant. In this study, we described clinical and microbiological characteristics of extra-intestinal diseases caused by *Aeromonas* species.

MATERIALS AND METHODS

In this retrospective study, we included those cases from whom *Aeromonas* spp. were isolated alone or along with another microorganism from extra intestinal sites after obtaining approval from the Institutional Ethics Committee from December 2015 to October 2016. Total 26 cases of *Aeromonas* were analysed retrospectively. Clinical features and the underlying co-morbid conditions were noted. Clinical samples evaluated for microbiological investigations were wound swabs (13), pus (8), tissues (8), bile (1)

and corneal scrapping (1). All clinical samples were cultured on 5% sheep blood agar and MacConkey agar after Gram staining and incubated at 37°C for 18-24 hours. Isolates were further identified by Gram staining, colony characteristics, biochemical tests like oxidase test, indole test, Voges-Proskauer test, triple sugar iron test, arabinose and esculin hydrolysis test [4] and finally by Matrix Assisted Laser Desorption Ionization Time-of-Flight (MALDI-TOF) VITEK[®]MS. Antimicrobial susceptibility testing of the isolates was done by VITEK[®]2 system (bioMérieux, Inc, Durham, NC).

Polymicrobial infection was diagnosed when another microorganism isolated along with *Aeromonas* spp. from the same clinical specimen.

Aeromonas spp. was identified as MDR, when they were non-susceptible to ≥1 agent in ≥3 antimicrobial categories [5].

STATISTICAL ANALYSIS

Patient demographics, clinical characteristics, co-morbid conditions and laboratory parameters were presented as mean±standard deviation, frequency and percentage as deemed appropriate.

RESULTS

Among the 26 patients diagnosed with *Aeromonas* infection, 84.6% (22/26) were male. The mean (SD) age of the patients was 41.58 (±17.86) years (range: 15-80 years). A majority of the patients had

a surgical admission (53.8%) followed by orthopedics (38.5%) and medicine (3.8%). The mean (SD) hospital stay was 16.55 (\pm 12.29) days.

Out of 26 individuals, 24 (92.3%) of them presented with SSTI at the time of admission. In 50% (12/24) patients, SSTI started after trauma to the site. The common site of infection was lower extremities (16 cases, 66.7%). Clinical presentation varied from localized infection to the severe gangrenous form. Out of 24 patients, 15 of them (62.5%) presented with gangrene of the extremities. Though 45.8% (11/24) of the patients with SSTI had underlying co-morbid conditions, none of them presented with invasive infection. Diabetes (5/24, 20.8%) was the most common underlying co-morbid condition. 54.2% (13/24) cases of SSTI were polymicrobial in nature. Organisms like *Staphylococcus aureus*, *Citrobacter* spp., *E.coli* and *Pseudomonas aeruginosa* were isolated along with *Aeromonas* spp. in polymicrobial infections.

Other than SSTI, 2 cases presented with cholangitis and keratitis. From both the cases *A. hydrophila* was isolated as a single pathogen. None of them had any underlying co-morbid conditions. Both the patients were young individuals. Patient demographics, clinical characteristics and co-morbid conditions associated with *Aeromonas* infections are mentioned in [Table/Fig-1].

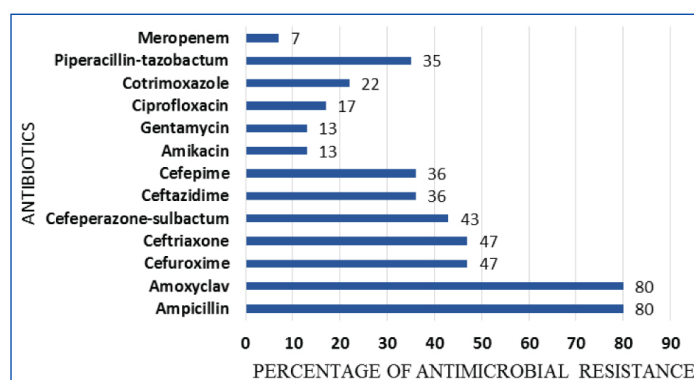
Most common isolated *Aeromonas* spp. was *A. hydrophila* (23/26, 88.5%) followed by *A. sobria* (11.5%). An 80% of *Aeromonas* were resistant to ampicillin, amoxy-clavulanic acid. Some of them even showed, resistance to second, third and even fourth generation of cephalosporin [Table/Fig-2]. A 13% of the *A. hydrophila* isolates were MDR. Carbapenem resistance was also noted.

Character	Number of Cases (26)	Percentage
Age (years)		
10-20	04	15.4
21-40	09	34.6
41-60	09	34.6
61-80	04	15.4
Gender		
Male	22	84.6
Female	04	15.4
Preceding trauma	12	46.2
Clinical Presentation		
Gangrene	15	57.7
Necrotizing fasciitis	03	11.5
Post-op wound infection	03	11.5
Localized wound infection	03	11.5
Cholangitis	01	3.8
Keratitis	01	3.8
Co-morbid conditions		
Diabetes	05	19.2
Hepatic disorders	01	3.8
Cardiovascular disorder	04	15.4
Renal disorders	01	3.8
Type of Infection		
Monomicrobial infection	13	50
Polymicrobial infection	13	50
Management		
Wound debridement+ antibiotic therapy	13	50
Only antibiotic therapy	4	15.4
Amputation done	9	34.6

[Table/Fig-1]: Patient demographics, clinical characteristics and co-morbid conditions associated with *Aeromonas* infections.

DISCUSSION

Aeromonas spp. is inhabitants of fresh and brackish water and increasingly having associated with diarrheal disease [1]. They also



[Table/Fig-2]: Antibiotic resistant pattern of the isolated *Aeromonas* spp.

have a significant role in the variety of extra-intestinal diseases in human. *A. hydrophila*, *A. caviae*, and *A. veronii* biovar *sobria* are responsible for more than 85% of human infections [6].

SSTI (92.3%) was the most common extra-intestinal manifestation by *Aeromonas* spp. in our study, similar to the other literature [7]. This infection commonly occurred in healthy young men, as reported elsewhere [8]. In 50% cases, trauma and concomitant exposure to contaminated soil (50%) had a significant role in the pathogenesis of SSTI [9]. The common site of infection was lower extremities (66.7%), also mentioned by Semel JD et al., [10]. These characteristics of the disease suggest that it is common in individuals who are more involved in outdoor activities and come in contact with contaminated soil. Mechanism of injuries involved road traffic accident (5 cases), accidental puncture wound (5 cases) and lacerated wound (2 cases). These types of injuries are more prone to contaminated soil exposure as mentioned elsewhere [11]. In the remaining 12 cases, there were underlying co-morbid conditions e.g., diabetes, hepatic disorders, renal disorders which might have predisposed the development of infection. Under these co-morbid conditions, *Aeromonas* can invade the blood stream [12]. But none of our cases had bacteraemia secondary to wound infection similar to earlier report by Lamy B et al., [6].

The various clinical types of SSTI are cellulitis, necrotizing fasciitis and localized wound abscess. Rarely, it progresses to severe form like myonecrosis or gangrene of the soft tissue due to production of extracellular products. But in our study, the typical clinical presentation was the gangrene of the infected tissue (15/24=62.5%) in contrast to previous report [9]. *Aeromonas* was found to be a sole causative agent of SSTI in 11 cases and 72.7% (8/11) of them presented with severe gangrenous form. Out of 8, one of them had diabetes. Presence of polymicrobial wound infection in 54.2% cases support the previous literature [7]. In polymicrobial infection, probably along with *Aeromonas*, other organisms like *S. aureus*, *Citrobacter* spp. and *P. aeruginosa* were also contributed to the wound pathology.

Aeromonas hydrophila (23 cases, 88.5%) were the most frequently isolated species causing SSTI infection, as mentioned by Janada JM et al., [11]. Isolation of *Aeromonas sobria* (11.5%) from the wound infection due to their cytotoxic activity is not very uncommon also [13]. Other than SSTI, we encountered cases of keratitis and cholangitis. In the event of keratitis, contact lens and the lens solution were the sources of infection. The isolate was sensitive to conventional ophthalmic antimicrobial agents like amoxicillin-clavulanic acid, gentamycin, ciprofloxacin and cotrimoxazole. The case was treated with topical fortified tobramycin (1.5%) and ciprofloxacin (0.3%) eye drops. Keratitis, due to the usage of contaminated contact lens is not very uncommon [14].

Post cholecystectomy, biliary tract infection by *Aeromonas* spp. can occur either through ascending route from the gastrointestinal tract, through hematogenous spread via portal vein or through contaminated water used at the time of operation [15]. Cholangitis was treated with a parenteral third generation cephalosporin.

Aeromonas strains are frequently resistant to penicillin, ampicillin, amoxicillin-clavulanic acid, cefazolin [16]. Eighty percent of our isolates also showed resistance towards amoxicillin-clavulanic acid and ampicillin similar to other studies due to the production of beta-lactamase enzyme [17-19].

We observed in our study, initial treatment for SSTI cases started with amoxicillin-clavulanic acid because most of the time it mimics staphylococcal or streptococcal skin infection [9]. But later in most of the cases antibiotic treatment shifted to ceftazidime along with aminoglycosides. Third generation cephalosporin e.g., ceftriaxone and piperacillin-tazobactam were used in few cases based on the antimicrobial susceptibility pattern. But we observed resistance to cefttriaxone (47%) and piperacillin-tazobactam (35%) also in our study, in contrast to the study by Zong Z et al., [20]. Fluoroquinolone resistance (17%) was similar to other study but in contrast resistance to co-trimoxazole was much less (22%) [2]. Multi drug resistance *Aeromonas* species have been reported globally by different authors [19,20]. Three of our *A. hydrophila* isolates were also MDR. They were resistant to ampicillin, amoxy-clavulanic, second, third and fourth generation cephalosporin, piperacillin-tazobactam, co-trimoxazole and ciprofloxacin. The MDR isolates were treated with carbapenem. Even carbapenem resistance was also noted in 7% cases.

Most of the SSTIs were managed by wound debridement followed by antibiotic therapy. Amputation was performed in few cases (9/26) due to severe gangrenous condition. Out of nine, three of them had diabetes also. All the cases responded clinically and microbiologically after the treatment.

Overview of various extra intestinal manifestations by *Aeromonas* spp. shows the necessity for routine identification of *Aeromonas* in the lab. The automated system along with the battery of biochemical require for their identification. Alone automated system can readily identify to the level of *A. hydrophila* group or *A. hydrophila/A. caviae*. However, these identification systems are often unable to detect interspecies differences. Phylogenetic analysis will provide a better result.

LIMITATION

Though we isolated *Aeromonas* spp. organism from different extra-intestinal sites, we could not be able to furnish several virulence factors responsible for these infections.

CONCLUSION

Extra-intestinal manifestations by *Aeromonas* spp. are not very uncommon in the coastal part of India. They were frequently isolated from post-traumatic wound site and rarely from some other sites like bile, corneal scrapping etc. The infections were treated either with a

combination of surgical debridement and antimicrobial therapy with a third generation cephalosporin and aminoglycosides or only with antimicrobial therapy. We observed MDR and carbapenem resistant *Aeromonas* spp. also in this part of India, which is a real issue of concern.

Our study will make the clinicians more alert about this organism and their antimicrobial susceptibility pattern that will be useful for future patient management.

REFERENCES

- [1] Mandell GL, Douglas RG, Bennett JE, Dolin R, eds. Mandell, Douglas, and Bennett's principles and practice of infectious diseases. Other gram negative bacilli. 7th ed. Philadelphia: Churchill Livingstone, 2010. pp. 3017-18.
- [2] Igbinosa IH, Igumbor EU, Aghdasi F, Tom M, Okoh AI. Emerging *Aeromonas* species infections and their significance in public health. The Scientific World Journal. 2012;2012:625023.
- [3] Von Graevenitz A. The role of *Aeromonas* in diarrhea: a review. Infection. 2007;35(2):59-64.
- [4] Carnahan AM, Behram S, Joseph SW. Aerokey II: a flexible key for identifying clinical *Aeromonas* species. J Clin Microbiol. 1991;29:2843.
- [5] Magiorakos AP, Srinivasan A, Carey RB, Carmeli Y, Falagas ME, Giske CG, et al. Multidrug-resistant, extensively drug-resistant and pandrug-resistant bacteria: an international expert proposal for interim standard definitions for acquired resistance. Clin Microbiol Infect. 2012;18(3):268-81.
- [6] Lamy B, Kodjo A, Laurent F, the colBVH Study Group, Laurent F. Prospective nationwide study of *Aeromonas* infections in France. J Clin Microbiol. 2009;47:1234-37.
- [7] Fraisse T, Lechiche C, Sotto A, Lavigne JP. *Aeromonas* spp. infections: retrospective study in Nimes University Hospital, 1997-2004. Pathol Biol. 2008;56:70-76.
- [8] Kelly KA, Koehler JM, Ashdown LR. Spectrum of extra-intestinal disease due to *Aeromonas* species in tropical Queensland, Australia. Clin Infect Dis. 1993;16:574-79.
- [9] Gold WL, Salt IE. *Aeromonas hydrophila* infections of skin and soft tissue: report of 11 cases and review. Clin Infect Dis. 1993;16:69-74.
- [10] Semel JD, Trenholme G. *Aeromonas hydrophila* water-associated traumatic wound infection: A review. J Trauma. 1990;16:69-74.
- [11] Janda JM, Abbott SL. Evolving concepts regarding the genus *Aeromonas*: an expanding panorama of species, disease presentations, and unanswered questions. Clin Infect Dis. 1998;27:332-44.
- [12] Ko WC, Lee HC, Chuang YC, Liu CC, Wu JJ. Clinical features and therapeutic implications of 104 episodes of Monomicrobial *Aeromonas* bacteraemia. J Infect. 2000;40:267-73.
- [13] Daily OP, Joseph SW, Coolbaugh JC, Walker RI, Merrell BR, Rollins DM, et al. Association of *Aeromonas sobria* with human infection. J Clin Microbiol. 1981;13(4):769-77.
- [14] Venkata N, Sharma S, Gora R, Chhabra R, Aasuri MK. Clinical presentation of microbial keratitis with daily wear frequent-replacement hydrogel lenses: a case series. Clao J. 2002;28:165-68.
- [15] Sung JY, Leung JW, Shaffer EA, Lam K, Olson ME, Costerton JW. Ascending infection of the biliary tract after surgical sphincterotomy and biliary stenting. J Gastroenterol Hepatol. 1992;7:240-45.
- [16] Motyl MR, McKinley G, Janda JM. In vitro susceptibilities of *Aeromonas hydrophila*, *Aeromonas sobria*, and *Aeromonas caviae* to 22 antimicrobial agents. Antimicrob Agents Chemother. 1985;28:151.
- [17] Vila J, Ruiz J, Gallardo F, Vargas M, Soler L, Figueras MJ, et al. In vitro antimicrobial susceptibility of clinical isolates of *Aeromonas caviae*, *Aeromonas hydrophila* and *Aeromonas veronii* biotype *sobria*. J Antimicrob Chemother. 2002;49:701.
- [18] Ko WC, Yu KW, Liu CY, Huang CT, Leu HS, Chuang YC. Increasing antibiotic resistance in clinical isolates of *Aeromonas* strains in Taiwan. Antimicrob Agents Chemother. 1996;40:1260.
- [19] Jones BL, Wilcox MH. *Aeromonas* infections and their treatment. J Antimicrob Chemother. 1995;35:453-61.
- [20] Zong Z, Lu X, Gao Y. *Aeromonas hydrophila* infection: clinical aspects and therapeutic options. Rev Med Microbiol. 2002;13(4):151-62.

PARTICULARS OF CONTRIBUTORS:

1. Assistant Professor, Department of Microbiology, Kasturba Medical College, Manipal University, Manipal, Karnataka, India.
2. Associate Professor, Department of Microbiology, Kasturba Medical College, Manipal University, Manipal, Karnataka, India.
3. Professor and Head, Department of Surgery, Kasturba Medical College, Manipal University, Manipal, Karnataka, India.
4. Professor, Department of Microbiology, Kasturba Medical College, Manipal University, Manipal, Karnataka, India.
5. Junior Resident, Department of Microbiology, Kasturba Medical College, Manipal University, Manipal, Karnataka, India.
6. Professor and Head, Department of Microbiology, Kasturba Medical College, Manipal University, Manipal, Karnataka, India.

NAME, ADDRESS, E-MAIL ID OF THE CORRESPONDING AUTHOR:

Dr. Chiranjay Mukhopadhyay,
Professor, Department of Microbiology, Kasturba Medical College, Manipal-576104, Udupi, Karnataka, India.
E-mail: chiranjay@gmail.com

FINANCIAL OR OTHER COMPETING INTERESTS: None.

Date of Submission: Jan 06, 2017
Date of Peer Review: Jan 24, 2017
Date of Acceptance: Feb 09, 2017
Date of Publishing: May 01, 2017